

## A Form of Progressive Cerebral Sclerosis in Infants associated with Primary Degeneration of the Interfascicular Glia.

By J. G. GREENFIELD, M.D., F.R.C.P.

SINCE the publication in 1912 of Schilder's important paper most cases of progressive diffuse cerebral sclerosis have been found to correspond more or less with the type which he described and the rather loose term of "Schilder's disease" has been used for them. Of recent years, however, there has been a tendency to separate these cases into different groups. Neuburger's classification has since been followed by Jakob, Bouman and others. He divided cases of diffuse sclerosis into (1) *Blastomatous*, which we should now recognize as diffusely infiltrating gliomas; (2) *Endogenous degenerative*; and (3) *Exogenous inflammatory*. Bielschowsky and Henneberg in an important recent article preserve the latter two classes, distinguishing them by the familial character of the degenerative type and by the presence of perivascular exudates in the inflammatory type. While it is obvious that there may be difficulty in fitting individual cases into appropriate classes, yet I am inclined to accept this distinction as generally true.

The case which Collier and Greenfield described in 1925 has since been proved to be a familial case, and I have also had the opportunity of examining the brain of a similar case belonging to another family. In both these families, as also in the families reported by Krabbe, Scholz and Bielschowsky and Henneberg, the disease came on at the same age and ran a very similar course in different members of the same family. This, however, is not the case in the family recorded by Symonds. In the cases which I have examined there has also been a difference in the histological picture of the two groups. The familial cases are characterized by the abundance of cells in the degenerating areas, by abnormal regressive types of neuroglia, and by an absence of lymphocytic exudate in the perivascular spaces. In the other type there is little to distinguish the demyelinated areas from the more recent plaques of disseminated sclerosis. The neuroglial reaction, the processes of myelin katabolism and the lymphocytic exudate in the two are quite comparable.

To these two types of diffuse sclerosis I now wish to add a third which appears to be sharply differentiated from the cases of Schilder's disease which have been so far described, and in some ways forms a connecting link between these and the diffuse sclerosis associated with micro- and macro-cephaly. Although in the two cases I am now presenting the children appeared to me normal during the first two years of life, and regressed rapidly in their mental development and neurological state, I feel that there is abundant evidence in the condition of the brains for assuming a developmental basis for the disease.

*Case I.*—B. R. (female), aged 3, was admitted to the National Hospital, Queen Square, under Dr. Critchley on January 12, 1932, and died on January 16. She was the only child of healthy parents, born at full term and weighing then 7½ lb. Pregnancy had been normal except that the mother had felt no movements until one week before her confinement. Labour was normal. The child had been lively and vigorous as an infant. She walked when eleven months old and talked at sixteen months. When eighteen months old she developed a squint which her mother attributed to a fall on her forehead. This was cured by glasses in six months. At the age of 22 months she had whooping-cough. At the age of 2 she began to fall backwards when walking, at first only two or three times a day, but progressively more often, so that in six weeks she could only walk when she held her mother's hand. By the time she was 2½ she could only stand when holding a chair and when she was 2½ she could do nothing but lie and had lost the use of her hands. The mother stated that there had been no staggering or unsteadiness, but simply progressive loss of strength. The child had also complained of a sensation of pins and needles at first in her legs and later in her arms which lasted for three months from the age of 2½ years. At this time she was quite bright, could see and speak normally and could move her head. She was sent first to an Orthopædic hospital in Birmingham, and after a

few days was transferred to Leicester Royal Infirmary. While there she changed rapidly, becoming speechless and senseless; she did not know her mother but turned her head continually from side to side as though it hurt her. After about eight weeks she appeared rather brighter, so that she knew her mother and father, but she seemed to have pain in her limbs. She appeared to be able to see at this time. During the last three months before admission to the National Hospital her eyesight had failed gradually, and for the last four weeks she had been blind. She was still able to swallow, but did not chew her food. There had been no convulsions at any time.

On examination in the National Hospital she was seen to be a fairly well nourished child of the normal size for her age. She lay in bed with the head retracted, the arms extended, the back bent forwards and the legs crossed. She whined continually. She was quite incoöperative and inattentive but she opened her eyes widely if her name was spoken in either ear. She seemed to be quite blind. The skull measured 49.5 cm. in its greatest circumference. The pupils reacted to light but constantly varied in size. The optic discs and

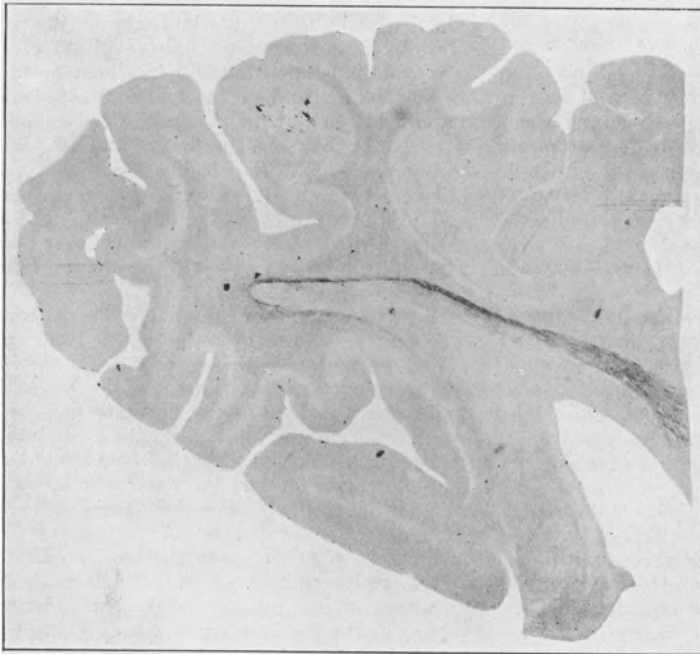

FIG. 1.—Horizontal section of the occipital lobe, stained by Weigert-Pal method and showing the general absence of myelinated fibres except in the optic radiations which stain fairly dark.

retinæ appeared normal. The corneal reflexes were absent, but pin-prick was responded to over the face and body by increased crying. The limbs tended to be held rigidly, especially if handled. The arms were held extended at the elbow, pronated with the fingers tightly closed. The legs were somewhat flexed at the hip, and extended at the knee, the left being crossed over the right. The feet were inverted. Passive movements of the head caused alterations in the position of the limbs to some extent. The deep and superficial reflexes were completely suppressed with the exception of the plantars. Here stimulation of the soles of the feet produced fanning of the toes on both sides with but little dorsiflexion of the great toe.

The child died from bronchitis on the fourth day after admission to the hospital.

The post-mortem examination was delayed for forty-four hours after death and the brain only was examined. The dura mater was slightly adherent to the skull. The brain appeared congested but otherwise its external surface looked normal. It was soft but not abnormally so. The occipital convolutions were small and numerous but there was no obvious shrinkage

of this part of the brain. The corpus callosum tore easily. On making horizontal sections through the brain the white matter appeared rather greyer than normal and the centrum ovale was much narrower than in Case II. In the occipital lobes the subcortical fibres looked rather whiter than the deeper zones of the centrum ovale, but the difference was but slight. The optic thalamus was shrunken, pale and firm and the internal capsule was softened in its inner zone and had split away from the optic thalamus and the body of the caudate nucleus. The Island of Reil was sunk rather deep beneath its opercula, apparently owing to the shrinkage of the optic thalamus.

The microscopic changes in this brain may be briefly summarized. With the Weigert-Pal stain the white matter of the hemispheres was practically unstained, with the exception of the optic radiations which stood out as darkly stained bands. Under higher magnifications numerous fine myelin sheaths were seen in most parts of the white matter, forming a thin network. They were rather more abundant in the immediately subcortical zone and some radial fibres could be seen passing into the cortex. The myelination was rather better preserved in the frontal than in the occipital cortex and in the lower parts of the hemispheres than in the upper.

The internal capsule was very pale, especially in its anterior limb and the posterior third of the posterior limb. The pyramidal fibres here were very thinly myelinated. In contrast to the pallor of the descending fibres the thalamo-striate fibres which passed across the internal capsule, as well as the fibre system of the caudate and lenticular nuclei and the outer part of the thalamus were well stained. In the mid-brain the pyramidal fibres were just evident as a pale grey mass in the centre of the pes, the frontal and occipital fibres here being unstained. In the medulla also the pyramids were pale, but with higher magnifications fairly numerous myelin sheaths could be seen which were definitely thicker than any in the pyramidal tracts at a higher level. The fibre systems of the mid-brain, pons and medulla were normally stained, but the cerebellar white matter was unstained over an area corresponding roughly to its lower half. The pallor here ran out into the stems of the cerebellar foliæ.

Along with this demyelination there was an intense neuroglial sclerosis, which certainly affected the demyelinated areas most intensely, but was also seen as an isomorphic increase in the areas in which myelination was normal. With Scharlach R. the white matter everywhere stained diffusely of a terracotta colour so that the areas of demyelination were not easily discerned, but with high magnifications, instead of the normal fibres, only a general granular appearance could be made out. Very numerous clear bodies which stained faintly with alum carmine were present in these areas. No red staining lipid could be seen except in the perivascular spaces. With Bielschowsky's method the axis cylinder network in the affected parts of the white matter was somewhat rarified but on the whole fairly well-preserved except in some parts of the occipital lobe.

In sections stained with hæmatoxylin or by Nissl's method, the most striking abnormality was a complete disappearance from the white matter of the small round nuclei of the interfascicular oligodendroglia. This was evident not only in the demyelinated areas, but also in such well-myelinated fibre systems as the thalamo-striate fibres and the hilum of the inferior olives.

There were also to be seen very numerous rather palely stained rounded masses, about  $20\ \mu$  in diameter, which were for the most part devoid of nuclei, although in some a small darkly stained dot, which may have represented a degenerated nucleus, was seen. The majority of these masses stained rather brightly with mucicarmine, and with Mallory's connective tissue stain and Heidenhain's Azan stain they stained blue, indicating their mucinoid nature. But a certain proportion stained red by the latter methods and were considered to be of lipid nature; these were most abundant in a zone one millimetre thick under the cortex. In the white matter of the hemispheres many of the perivascular spaces were greatly distended by the accumulation in them of mucinoid masses. Mucinoid masses of smaller size were seen in the pyramidal tract throughout the brain-stem, as well as in the cerebellar hemispheres, and collections of the lipid granules with a few small mucinoid masses were seen in some well myelinated fibre systems, such as the thalamo-striate fibres, the transverse fibres of the pons and the hilum of the inferior olives.

*Case II.*—A. H. (male), aged 3, was admitted to the National Hospital in January, 1932, under Dr. Collier.

His mother and father were healthy and were not blood relations. They had had four children. The first died at the age of 2 years and 11 months. He was a boy born at full

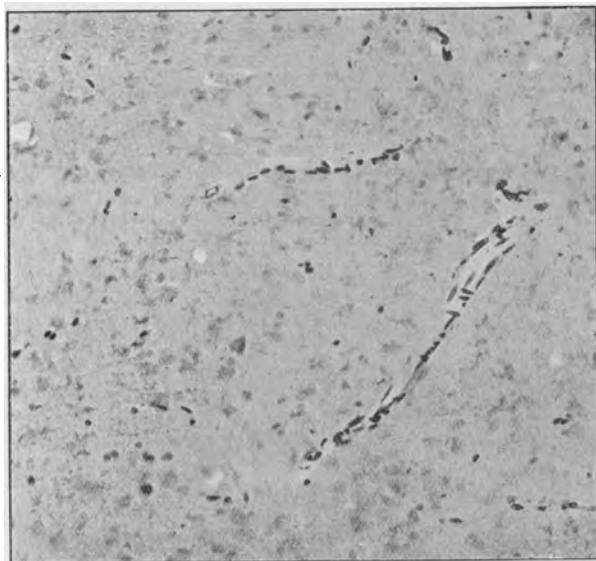


FIG. 2.—White matter of centrum ovale. The only nuclei seen are those round small vessels and isolated nuclei of astrocytes and microglia. Masses of lipoid and mucinoid material are faintly stained.

Iron hæmatoxylin, van Gieson (celloidin section).

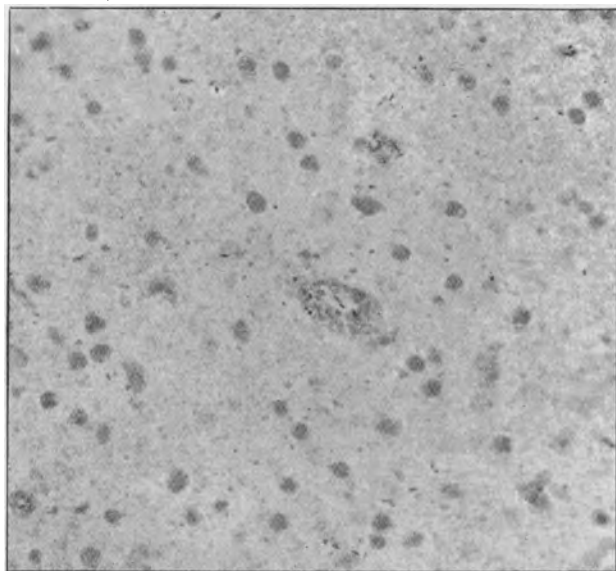


FIG. 3.—White matter of centrum ovale, stained by mucicarmine and alum hæmatoxylin. The mucinoid masses which stain fairly deeply are scattered through the tissues and distend the sheath of a small vessel. The "lipoid" masses do not stain. Note that the great majority of the mucinoid masses are devoid of nuclei.

term; he appeared normal at birth and sat up at 10 months, but never walked or talked. From the time of his birth his head was large and gradually increased in size. He was seen at the National Hospital in 1923, and the diagnosis then made was that of hydrocephalus. He had no fits and was not blind.

The second child was a boy of 10, and the third a girl of 7. Both of these were examined by Dr. Carmichael in the out-patient department and found to be perfectly normal, healthy children. The head circumference of the elder was 21 in. and of the younger 20½ in.

The patient was a full-time child. The birth was normal. He was breast-fed for ten months. He sat up and talked at the normal ages, but had never walked. At the age of 12 months he had measles and was ill with bronchitis after this for three or four weeks, but after this he recovered, and at the age of 18 months could roll and crawl about the floor. When he tried to walk his legs became crossed. Otherwise he remained in good health till three months before admission to hospital, i.e., at the age of 2 years and 9 months, when he became ill with "influenza." He ate very little, slept and dozed most of the time and his head seemed heavy. Since then he had never sat up. Two weeks later his speech became indistinct, and, after a further two weeks, he ceased talking altogether. For the last six weeks his mother had noticed that when he cried he became stiff; there was no loss of consciousness or fits at any time, nor any vomiting. The child ate and slept well, but had been increasingly irritable. The mother thought that he was still bright and intelligent and that his sight and hearing were unaffected. His head was said to have grown large gradually.

He was found on examination to be a thin, small child with a large head. He lay quietly on his back, but every ten minutes or so he appeared to have an attack of pain, his back became arched, and his head retracted, and he gave sharp cry. At first all his limbs were rigidly extended, but soon the left arm was flexed and drawn over to the right shoulder. The pupils reacted slowly to light. The fundus oculi was normal except for slight fullness of the retinal veins. The corneal reflexes were present, but he did not respond to pin-pricks. His limbs were held rigid; the left arm and the legs extended, and the right arm flexed at the elbow and fingers. The tendon-jerks were present but rather feeble, the abdominal reflexes were absent, and the plantars of the Babinski type. A lumbar puncture was performed on January 7. The cerebrospinal fluid was under low pressure, 96 mm. The fluid was clear and colourless. It contained 120 mm. of protein per 100 c.c., and gave a positive Pandy and a weakly positive Nonne-Apelt reaction. No cells were seen in it. The child died the same evening. The clinical diagnosis was "hydrocephalus."

A post-mortem examination was made by me on the following day. There was comparatively little thinning of the skull, and no evidence of hydrocephalus, or of thrombosis of the venous sinuses. The cerebral hemispheres felt very firm, almost hard, whereas the pons and cerebellum had the normal consistency. The brain weighed 1,287 grm., and the brain-stem and cerebellum 132 grm. The relation of the weight of the cerebral hemispheres to that of the brain-stem and cerebellum was therefore as 8.75 is to 1, the normal, according to Dunlap, being 7 to 1.

On section the white matter of the hemispheres appeared relatively bulky and rather less white than normal. There was in this case no definite sclerosis of the optic thalamus. Histologically, the changes in this brain were so similar to those in Case I that it is only necessary to refer to the points in which they differed. On the whole they were of rather slighter severity; thus there was a little more preservation of myelin sheaths in the cerebral hemispheres, and there was no very obvious demyelination of the cerebellum, although the lower half stained less deeply than the upper half by the Weigert-Pal process. The preservation of the optic radiations, and the relative sparing of the pyramidal fibres in the pes were identical with those seen in Case I. Mucinoid and lipid masses were also present although perhaps not quite so numerous, but there was a difference here in that the lipid masses everywhere outnumbered those of mucinoid nature, and there was no accumulation of the latter in the perivascular spaces. The interfascicular oligodendrocytes were also severely degenerated, but had not disappeared so completely as in Case I. Although large areas of the white matter of the hemispheres contained no cells of this nature, a few degenerated oligodendrocytes could be seen in some of the less affected fibre systems in the brain and brain-stem, and in the cord they presented the normal numbers and appearances.

It is noteworthy also that while the pyramidal tracts in the cord, as throughout the brain-stem, were very palely stained by the Weigert-Pal method, they contained, in the cord, no

mucinoid or lipid masses, although in the brain-stem, as far down as the medulla, they were dotted with small globules of this nature.

The appearances of the nervous system in this case could thus be interpreted as an earlier stage of the same disease process as in Case I. This was in accord with the shorter history of progressive symptoms, which had been present for only three months before death.

The facts in these two cases may be briefly summarized as follows. The children were normal for the first two years of life except for a condition of diplegia in the second. Thereafter, and especially following febrile illnesses, they regressed mentally and physically, first losing the powers of walking and talking, and then of sight, hearing and recognition. Death occurred in a state of almost complete decerebration at the age of 3.

Post mortem there was found a condition of diffuse sclerosis of the cerebral hemispheres which spared the optic radiations and to some extent the pyramidal tract, but affected in Case I the inner nucleus of the thalamus and the lower half of the cerebellum. The state of myelination thus corresponded very closely to that in the brain of a baby between two and three months of age. This absence of myelin was associated with a complete or almost complete absence of interfascicular oligodendroglia, not only in the affected areas, but also in neighbouring well-myelinated tracts. There was little evidence of myelin destruction, unless the presence of Scharlach staining lipid round the vessels could be accepted as such, and there was no mobilization of fat phagocytes. On the other hand there was abundant deposition of mucinoid and lipid material in the unmyelinated areas, in the form of extracellular masses.

On these facts we must base our speculations as to the cause of the disease and its pathogenesis. The developmental nature of the condition is indicated by the distribution of the demyelination. Evidently the tracts which myelinate first are those which survive. But there is considerable evidence of degeneration in some of those which begin to myelinate at birth, as shown by the swellings on the myelin sheaths in the optic nerves, the optic radiations, and the thalamo-striate fibres. The progressive nature of the disease is also in favour of a degeneration rather than aplasia of myelin. On the other hand the almost complete absence of fat granule cells, except round the vessels, suggests either a gradual impoverishment of myelin sheaths, or an abnormal form of myelin, which in breaking up into simpler lipoids did not give rise to the usual phagocytic reaction.

The chief difficulty in these cases is to reconcile this abnormal or imperfect myelination with the absence of oligodendroglia. Here also we are helped by a study of development. At birth there are very numerous cells in the white matter, but only a few of them have the typical small round nucleus of the oligodendrocytes. In most the nucleus is larger, oval and more vesicular belonging to oligodendroblasts and young astrocytes. And in some nerve-bundles such as those which pass into the lenticular nucleus there are few interfascicular cells, although later in life oligodendrocytes are numerous in this situation. Evidently therefore the oligodendroglia continues to develop after birth. There is now considerable evidence that this development is associated in some way with myelination. That was suggested by Del Rio Hortega in 1927, and it has been supported by the observation of Berliner that whereas in most animals oligodendroglia cells are not found in the retina, they are present among the myelinated opaque nerve-fibres which are normally present near the optic disc of the rabbit. He suggested that, as there is no lamina cribrosa in the rabbit, there was no barrier to the migration into the retina of oligodendrocytes, which, having arrived there, caused the formation of myelin round the nerve-fibres. Now it is well known that in many cases of Schilder's disease the oligodendroglia disappears from the demyelinated centres, although it is normally present in the degenerating margin. Del Rio Hortega, examining a case of this kind, was inclined to the view—which has since been

adopted by Kernohan—that the degeneration of oligodendroglia goes so much hand-in-hand with the demyelination as to suggest that it is primary and the demyelination secondary. Dr. Collier and I put forward a very similar theory in 1924, although we knew nothing then about the function of the oligodendroglia. We suggested that in Schilder's disease the primary attack of the supposed virus was on those neuroglial cells of the white matter which had to do with the nutrition of the myelin sheaths. Levaditi has gone so far as to suggest that in Schilder's disease the normal nutritive function of the oligodendroglia is reversed by the action of the supposed virus to a phagocytosis or at any rate katabolism of myelin. We now know that the case which Dr. Collier and I described was a familial one, and therefore it was presumably not due to a virus. But of the early degeneration of oligodendroglia in Schilder's disease there seems little doubt.

Another fact about the disease which has emerged is the formation of *mucinoid material*. This was found first by Bailey and Schaltenbrand, and has since been observed by many writers. Most of them accept the view of Grynfeldt of Montpellier that the mucinoid material arises in the bodies of the oligodendrocytes but later becomes extracellular. But in none of the cases of Schilder's disease that I have seen, is the formation of mucinoid substance so abundant as in those I have just described. Further the majority of the mucinoid balls in my cases appear to be devoid of nuclei, although one can see here and there a minute speck of darkly staining nuclear material. The question therefore arises whether these mucinoid balls are to be considered as evidence of pre-existing oligodendrocytes, or as a special type of myelin degeneration. In my first case, in which there is a more complete disappearance of oligodendroglia, they are found distending the perivascular sheaths, a fact which suggests that they have been present for a longer time than in the second case.

These facts give warrant for postulating a close association between demyelination and primary degeneration or faulty development of the oligodendroglia. In my cases the hypothesis of faulty development seems the more plausible one. Either there may have been a failure in the differentiation of oligodendroblasts into oligodendrocytes, or they may have failed to migrate into the areas which are last myelinated. Along with this the myelination has been imperfect in quality and in degree and, lacking the nutritive action of the oligodendroglia, it has been unusually vulnerable. There is no direct evidence as to which of these structures is primarily at fault; that is to say whether the myelin suffers from the absence of oligodendroglia, or whether the failure of the oligodendroglia is due to some fault in the myelin. The absence of oligodendroglia and the presence of abnormal lipid material in certain well-myelinated fibre systems such as the thalamo-striate fibres and those in the hilum of the olives, would lead one to suppose that the myelin suffers secondarily to degeneration of the oligodendrocytes. But Bielschowsky and Henneberg have advanced the alternative hypothesis to explain certain familial cases of Schilder's disease. Accepting the evidence that some forms of amaurotic family idiocy are due to a faulty lipid metabolism in the body generally, which affects not only the nerve-cells but the reticulo-endothelial system as well, they suggest that their cases of Schilder's disease also are due to the provision of abnormal lipids for the nutrition of the myelin sheaths. The general tendency nowadays is to consider familial diseases as due to metabolic disturbances rather than to primary cellular decay, and it may well be that the absence of some essential ingredient of the myelin from the blood of the infant may have slowed down and eventually arrested the migration and differentiation of the oligodendroglia. It is to be supposed that during intra-uterine life this constituent was supplied by the mother's blood, and possibly later by the mother's milk, so that development proceeded normally until these sources of supply were withdrawn.

Whether primarily due to cellular decay or to metabolic disturbances, this form

of cerebral sclerosis appears to have been definitely due to some developmental error, the effects of which began to appear soon after birth and were intensified by the febrile illnesses from which the children suffered during the second and third years of life.

## BIBLIOGRAPHY.

- [1] BAILEY, P., and SCHALTENBRAND, G., *Deut. Zeit. für Nervenheilk.*, 1927, xcvi, 231. [2] BERLINER, M. L., *Archives of Ophthalmology*, 1931, vi, 740. [3] BIELSCHOWSKY, M., and HENNEBERG, R., *Journal für Psychologie und Neurologie*, 1928, xxxvi, 131. [4] BOUMAN, L., *Brain*, 1924, xlvii, 453. [5] COLLIER, J., and GREENFIELD, J. G., *Brain*, 1924, xlvii, 489. [6] DEL RIO HORTEGA, *Memorias de la Real Sociedad de Historia Natural*, 1928, xiv, 5. [7] GRYNFELT, E., *Compt. Rend. de la Soc. de Biol.*, 1923, lxxxix, 1264. [8] JAKOB, A., *Zeit. für die ges. Neurologie und Psychiatrie*, 1915, lxxv, 290. [9] KRABBE, K., *Brain*, 1916, xxxix, 74. [10] LEVADITI, C., *Annales de l'Institut Pasteur*, 1930, xlv, 673. [11] NEUBÜRGER, *Zeit. für die ges. Neurologie und Psychiatrie*, 1921, lxxiii, 336. [12] SCHILDER, P., *Zeit. für die ges. Neurologie und Psychiatrie*, 1912, x, 1. [13] SCHOLZ, W., *Zeit. für die ges. Neurologie und Psychiatrie*, 1925, xcix, 651. [14] SYMONDS, C. P., *Brain*, 1928, li, 24.

Dr. CARNEGIE DICKSON said that Dr. Greenfield had gone far to prove the part of his thesis which suggested the dependence of myelination—and hence also of demyelination—upon the functions of the oligodendroglial cells. He (the speaker) had studied two of the so-called familial cases of Schilder's encephalitis, and the nature of the glial cells taking part in the progressive gliosis which led to the contraction of the affected white matter depended largely on the particular areas chosen for section. Thus proliferation of astrocytes was found especially in the deep cortical region, oligodendroglial proliferation in some parts and tracts of the white matter, e.g. the surfaces of the corpus callosum, etc., with degeneration and disappearance of these cells in the deeper parts, e.g. of the centrum ovale. In addition to a "deficiency element" in the familial cases, whether of the nature of the lack of some organ secretion or the like, there might also be the predisposition to a chronic infective process, just as in scurvy the streptococci and other organismal invaders were given their chance to attack, even although some authorities were inclined to attribute the different types of sclerosis to one or other of these factors, and not both combined.

## The Clinical Significance of Variations in Tickle Sensibility.

By E. A. BLAKE PRITCHARD, M.D.

The word tickle is popularly used for two quite different sensations. In a normal adult if a hair is passed across the upper lip, across the nape of the neck, or beneath the ears, the person examined will almost invariably complain of a sensation which he calls tickle. A sensation which he will identify with this can usually be obtained from the palm of the hand and from all parts of the body which are definitely hairy.

Again, most persons will acknowledge a sensation of a peculiar nature when firm pressure with the fingers is passed down the side of the chest below the axilla, and they call this sensation also tickle. There are some immediately obvious differences between these two sensations: closer examinations show that there are also more fundamental differences which demand complete separation of these two varieties of tickle.

They differ importantly, both in the nature of the stimulus required to elicit each and in the total reaction to which such stimulation gives rise.

For that which may be for the moment called the upper-lip or hairy tickle, the stimulus has to be exceptionally light, the drawing across of a hair or of a wisp of wool: any more firm or more extensive pressure fails completely. In many persons a light brush drawn firmly across the upper lip fails to elicit tickle although the similar application of one or two of its component hairs results in intense tickling.

For the chest-wall-tickle such light-pressure stimuli are always inadequate: the pressure must be of the order of about half a pound or more.